

*Research Article***Role of magnetic resonance spectroscopy in evaluation of prostatic tumors.**

Emadeldeen S. Ali; MD, Saad R. Abdulwahed Hussein; MD, Tarek M. Mohamed Mansour; MD and Mostafa A. Gaber Hasan; Msc.
Department of Radiodiagnosis Al-Azhar University, Assiut,

Abstract

Background: Magnetic resonance imaging may improve the staging of prostate cancer compared with clinical evaluation alone, computerized tomography, or trans-rectal ultrasound, and it allows simultaneous and detailed evaluation of prostatic, peri prostatic, and pelvic anatomy. Magnetic resonance imaging and magnetic resonance spectroscopic imaging (MRI/MRSI) allow better visualization of the zonal anatomy of the prostate and better delineation of tumor location, volume, and extent (stage). Metabolic criteria used to identify and localize prostate cancer with MRI/MRSI have been standardized, thus improving the accuracy of the examination and limiting inter observer variations in interpretation. **Objective:** The aim of this study is to evaluate the diagnostic efficiency of MR spectroscopy in evaluating the prostatic tumors in the form of differentiation of benign from malignant prostatic tumors. **Patients and methods:** This study was conducted on 50 patients with prostatic tumors at Radiodiagnosis Department Al-Azhar University, Assiut, during the period from October 2015 to March 2018, all patients were subjected to complete history taking, clinical examination, laboratory assessment (PSA), trans-rectal ultrasonography, MRI and prostatic biopsy. **Results:** In our study, we proved high sensitivity and specificity of MP-MRI reaching 100% and 96.67% respectively in the diagnosis of patients with elevated PSA level and hard nodule by DRE. **Conclusion:** In our research we analyzed the combined use of T2-weighted imaging and H-MRS to detect prostate cancer accurately. We hypothesized that combined information of non-invasive morphologic and functional MR techniques, multiparametric MR imaging approach rather than use of either sequences alone, could easily improve the detection, localization and grading of prostate cancers.

Keywords: Prostate, cancer, MRI, spectroscopy.

Introduction

The prostate is an important organ in the male urogenital system. The prostate gland is the most frequently diseased organ in men. Space occupying lesions are the most common lesions in men over the age of sixty five year. Although digital rectal examination has been the primary method for evaluating these lesions, its limitations in both detection and staging are well recognized (De Meerleer, Fonteyne et al., 2007).

Prostate cancer is one of the most common malignancies in elderly men. The posterior and lateral aspects of the prostate are the zone in which 70% of prostate cancers arise. Cellular proliferation in the transitional zone results in benign prostatic hyperplasia (Pucar, Shukla-Dave et al., 2005).

Patients and method

We carried out a prospective study on 50 male patients between October of 2015 and March of 2018, their ages are ranging from 45 to 90 years with mean age (65.12±9.94 years), all the patients were referred from urological out-patient clinics complaining from variable urological symptoms.

All the patients were subjected to the following:

- Complete history taking.
- Local examination.
- Laboratory investigation including urine analysis, prostatic surface antigen (PSA) and histopathological examination of the transrectal biopsy.
- Imaging modalities including trans-rectal ultrasonography, transrectal prostatic biopsy and magnetic resonance imaging (MRI).

These examined patients were presented by either raised PSA > 4ng/dl or by hard nodule by digital rectal examination.

Examination protocol

Preparation and positioning of the patient: the patient preparation for examination consisted of four-hour fasting. Reassurance of the patient from the entrance to the scanning room must be a rule, including an appropriate knowledge of the whole process. No intestinal lavage was performed.

All examinations were performed using a 16-channel 1.5 T MR scanner (Philips Achieva) pelvic-phased array coil, at the Department of radio-diagnosis of Al-Azhar university.

In the sagittal plane, the positioning was performed following the longest axis of the prostate, aligning the pubic symphysis with the lumbar spine. In the coronal plane, the block was angled according to the longest axis of the prostate. In the axial plane, the angle was according to the longest prostate axis, in such a manner to position the images from the pubic symphysis to the end of the seminal vesicles.

Protocol for spectroscopic data acquisition: Multi-voxel H-MR Spectroscopy imaging is followed with application of an automatic shimming algorithm and adding manual post shimming optimizing field homogeneity followed by frequency selective fat and water suppression using a box adjusted to prostate for quantitative detection of choline, citrate and creatinine. (TR 1132 and 1500, TE 110 and 120, SPIR1500, ACQ matrix 4X5, slices 55X55X55 and 5 slice).

Results

12 patients of the study (24%) presented by retention, 12 patients (24%) presented by dysuria, 10 patients (20%) presented by frequency, 14 patients (28%) presented by

hematuria and the last two patient (4%) presented by hematospermia.

32 patients (64%) were referred with raised PSA levels (more than 10 ug) while the other 18 patients (36%) were referred with low PSA levels (less than 10 ug).

32 patients (64%) from 50 patients their lesions were organ confined (the lesion is localized in the prostate only), 18 patients (36%) were with local advanced lesions (the lesion extending outside the prostate).

The histopathological results of the transrectal prostatic biopsy revealed that 18 cases (36%) had benign prostatic hyperplasia and 32 cases (64%) had malignant lesions which included 26 cases (52%) of adenocarcinoma, 4 cases (8%) of metastases and 2 cases (4%) of lymphoma. US, conventional MRI, DWI and MRS examinations were done for all cases.

In our research we analyzed the combined use of T2-weighted imaging and H-MRS to detect prostate cancer accurately. We hypothesized that combined information of non-invasive morphologic and functional MR techniques, multiparametric MR imaging approach rather than use of either sequences alone, could easily improve the detection, localization and grading of prostate cancers. In this research; T2W imaging had (95.65%) sensitivity and (70%) specificity, H-MRS acquisition with Cho/Cit ratio had 91.3% sensitivity and 96.6% specificity and Cho + Cre/Cit ratios had 91% sensitivity and 100% specificity.

We proved high sensitivity and specificity of multi-parametric MRI reaching 100% and 96.67% respectively in the diagnosis of patients with elevated PSA level and hard nodule by DRE

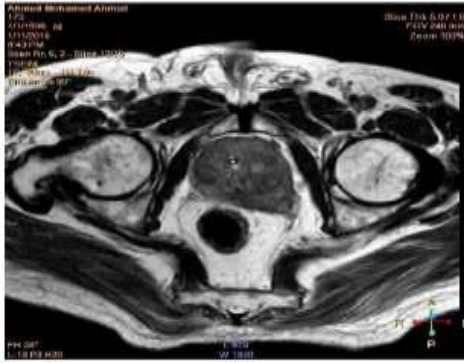

Fig. A.

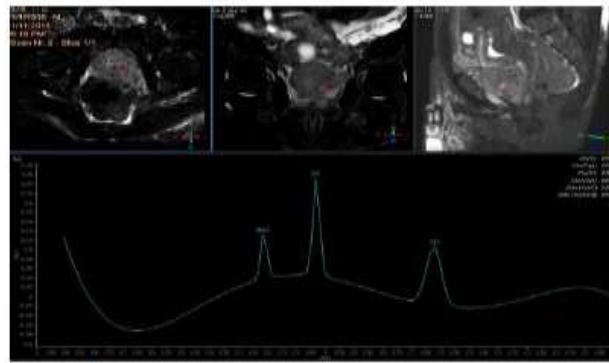


Fig. B

Figure: left side capsular bulge with fat stranding and spectral pattern of cancer prostate (selected case).

Discussion

Prostate cancer screening fundamentals are based on the fact that patients diagnosed at screening tend to present a more favorable stage as compared with those clinically diagnosed, with a possible decrease in the rate of specific mortality due to prostate cancer. Magnetic resonance imaging is commonly utilized for the tumor staging after a diagnosis is established by prostatic biopsy.

When the disease is confined to the prostate, the capsule will appear intact, even if there is an extensive contact or regular bulging between the capsule and the tumor.

Conclusion

The implantation and standardization of magnetic resonance spectroscopy imaging allowed the acquisition of relevant data for the presumptive diagnosis of the presence of prostate cancer, combining the MR images with metabolic data from MRSI.

Recommendation

1. Larger studies should be made to prove higher statistical analysis.
2. Dynamic contrast resonance imaging should be used as a functional MRI tool for accurate diagnosis of prostate cancer.
3. Radical prostatectomy should be used instead of TRUS biopsy for better diagnosis of prostate cancer.

References

1. Carroll, P. R., F. V. Coakley and J. Kurhanewicz (2006). Magnetic resonance imaging and spectroscopy of prostate cancer. *Reviews in urology* 8(Suppl 1): S4.
2. Claus, F. G., H. Hricak and R. R. Hattery (2004). "Pretreatment evaluation of prostate cancer: role of MR imaging and 1H MR spectroscopy." *Radiographics* 24 (suppl_1): S167-S180.
3. De Meerleer, G. O., V. H. Fonteyne, L. Vakaet, G. M. Villeirs, L. Denoyette, A. Verbaeys, N. Lummen and W. J. De Neve (2007). Intensity-modulated radiation therapy for prostate cancer: late morbidity and results on biochemical control. *Radiotherapy and Oncology* 82(2): 160-166.
4. Hoeks, C. M., J. O. Barentsz, T. Hambrock, D. Yakar, D. M. Somford, S. W. Heijmink, T. W. Scheenen, P. C. Vos, H. Huisman and I. M. van Oort (2011). "Prostate cancer: multiparametric MR imaging for detection, localization, and staging." *Radiology* 261(1): 46-66.
5. Jemal, A., T. Murray, E. Ward, A. Samuels, R. C. Tiwari, A. Ghafoor, E. J. Feuer and M. J. Thun (2005). "Cancer statistics, 2005." *CA: a cancer journal for clinicians* 55(1): 10-30.
6. Kurhanewicz, J., D. B. Vigneron, R. G. Males, M. G. Swanson, K. Y. Kyle and H. Hricak (2000). "The prostate: MR imaging and spectroscopy: present and future." *Radiologic Clinics of North America* 38(1): 115-138.